



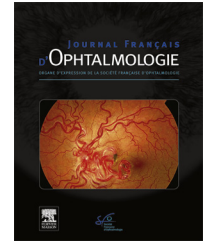
ELSEVIER

Disponible en ligne sur

ScienceDirect
www.sciencedirect.com

Elsevier Masson France

EM|consulte
www.em-consulte.com



ORIGINAL ARTICLE

Preloaded Monoka (Lacrijet) and congenital nasolacrimal duct obstruction: Initial results

Sonde Monoka préchargée Lacrijet (Ljc) et imperforations lacrymo nasales congénitales : premiers résultats

B. Fayet^{a,*}, E. Racy^b, J.-M. Ruban^c, J.A. Katowitz^d,
W.R. Katowitz^d, D. Brémond-Gignac^e

^a Department of Ophthalmology, Hospital Cochin, University of Paris VI - Medical School, 22, rue du Faubourg-Saint-Jacques, Paris, France

^b ENT, Fondation Saint-Jean-de-Dieu, 02, rue Rousselet, 75007 Paris, France

^c Department of Ophthalmology, Hospital Edouard Herriot, Place d'Arsonval, Lyon, France

^d Division of Ophthalmology, The Children's Hospital of Philadelphia and The Edwin and Fannie Gray Hall Center for Human Appearance, University of Pennsylvania, Philadelphia PA, USA

^e Department of Ophthalmology, Hôpital Necker-Enfants malades, 149, rue de Sèvres, 75015 Paris, France

Received 16 October 2020; accepted 5 November 2020

KEYWORDS

Congenital nasolacrimal duct obstruction;
Monocanalicular;
Valve of Hasner;
Lacrimal intubation;
Lacrimal probing;
Late probing;
Metal to metal test;
Masterka;
LacriJet;
Pushed intubation;

Summary

Study objective. – To study the performance of a pre-loaded Monoka stent in the management of congenital nasolacrimal duct obstruction (CNLDO).

Study design. – Non-randomized study of consecutive cases.

Materials and methods. – A preloaded classic Monoka silicone stent contained entirely inside its introducer (Lacrijet) was used to treat a consecutive series of subjects with CNLDO over an 11-month period (May 2019–March 2020). Only subjects with chronic symptomatic CNLDO were included. Subjects with intermittent tearing, canalicular pathology, trisomy 21, facial cleft, or history of lacrimal surgery were excluded. Intraoperative findings were recorded, including the degree and location of the nasolacrimal obstruction, successful metal to metal contact with the probe, any difficulties encountered by the Lacrijet device itself, procedure duration, tolerability of the fixation punctal plug, and finally, inspection of the stent after withdrawal of the inserter. Functional success was defined as disappearance of all symptoms of epiphora.

* Corresponding author.

E-mail address: bruno.e.fayet@gmail.com (B. Fayet).

Anchoring punctal
plug;
Simple stenosis;
Bony stenosis

Results. – A total of 45 preloaded Monoka Lacrijet stents (Lcj) were placed consecutively in 38 children. The mean age was 27.9 months (12–78 months). The mean procedural duration was 2.8 minutes (range: 1–10 min). The overall success with disappearance of all symptoms of epiphora was 88.8% (40/45). Surgery in cases of simple mucosal stenosis was successful in 92.2% (35/38) of cases, with a mean follow-up time of 7.9 months (range: 1 to 12 months). The duration of stent intubation was for this group was 32 days (range: 1–103). The surgical outcomes for the other 7 cases with more complex intraoperative findings are summarized in the publication. All withdrawn probes were intact.

Conclusions. – The Lacrijet stent system is a simple and reliable pushed intubation device for CNLDO in appropriately selected cases where bony stenosis of the canal is minimal.

© 2021 Published by Elsevier Masson SAS.

MOTS CLÉS

Obstruction
congénitale du canal
naso-lacrimal ;
Monocanaliculaire ;
Membrane de
Hasner ;
Intubation
lacrymale ;
Sondage lacrymal ;
Sondage tardif ;
Test métal sur métal ;
Masterka ;
Lacrijet ;
Intubation poussée ;
Ancrage du bouchon
ponctuel ;
Sténose simple ;
Sténose osseuse

Résumé

Objectif de l'étude. – Étudier le comportement d'une Monoka pré chargée dans le traitement des imperforations lacrymo-nasales.

Nature. – Étude non randomisée de cas consécutifs.

Matériels et méthodes. – Une sonde Monoka classique préchargée (Lacrijet), contenue entièrement à l'intérieur de son guide de pose a été utilisée pour traiter une série consécutive d'imperforation lacrymo-nasale. L'étude s'est étendue sur une période de 11 mois (mai 2019–mars 2020). Seule les symptomatologies permanentes ont été incluses. Ont été exclus: symptomatologies intermittentes, pathologie canaliculaire, trisomie 21, fente faciale, antécédents de chirurgie lacrymale. La sélection per opératoire notait : l'intensité et la localisation de la sténose lacrymo-nasale, le test du contact métallique, les difficultés peropératoires, la durée de l'intervention chirurgicale, la tolérance de la tête de fixation. L'état de la sonde retirée au terme de sa période d'intubation était noté. Un succès fonctionnel a été défini par la disparition de tous les symptômes.

Résultats. – Au total, 45 sondes Lacrijet (Ljc) ont été placées consécutivement chez 38 enfants. L'âge moyen était de 27,9 mois (12 à 78 mois). Le temps opératoire chirurgical moyen était de 2,8 minutes (intervalle : 1 à 10 min). Le succès global (Disparition de tous les symptômes) était de 88,8 % (40/45). La chirurgie en cas de sténose muqueuse simple il était de 92,2 % (35/38) des cas avec un suivi moyen de 7,9 mois (intervalle : 1 à 12 mois). La durée de l'intubation était pour ce groupe de 32 jours (intervalle : 1 à 103). Les résultats chirurgicaux pour les 7 autres cas plus complexes sont résumés dans la publication. Les sondes retirées étaient toutes intactes.

Conclusions. – Le système de Monoka préchargée semble être simple à mettre en œuvre dans les imperforations lacrymo-nasale muqueuses. Une sélection rigoureuse est indispensable.

© 2021 Publié par Elsevier Masson SAS.

Precis

A pre-loaded monocanicular stent on an insertion device has been created for greater ease with lacrimal intubation.

Introduction

After the age of one year, the management of cases with persistent congenital nasolacrimal duct obstruction (CNLDO) is controversial [1].

The same symptomatology corresponds to a spectrum of causes leading to CNLDO. Cases are only morphologically distinguishable in rare instances such as facial clefts affecting the outflow system. Lacrimal probing (LP) allows clear

differentiation between the choice of simple stent intubation and all others [2–6], but the tactile sensation is not sufficiently precise to accurately identify the exact problem [7,8]. While diagnosis might be enhanced by utilizing intracanalicular, nasolacrimal duct and intra-nasal endoscopy as well as imaging studies. Use of such techniques as first-line diagnostic steps would be needlessly expensive as well as potentially causing iatrogenic complications. Clinical experience has demonstrated favorable outcomes in most cases without use of these additional diagnostic tests.

The most efficient treatment is difficult to extract with confidence from review of the literature. The impact of age at the time of surgical intervention is somewhat contentious, but does suggest that early treatment is better [1]. The success rate of a simple lacrimal probing (LP) done after one year of age varies from 50 to 90% [3,9–11]. The success rate




Figure 1. Description. The preloaded Monoka™ (Lcj™) is a monocanalicular nasolacrimal duct intubation stent with stable self-retaining punctal fixation. The handpiece is composed of a cylindrical body comprising an introducer connected to a piston. A safety pin blocks untimely piston movements. The introducer is based on the principle of a sailboat head foil, comprising an extremely narrow gutter. The Monoka™ stent is comparable to the lacing rope and is entirely contained in the introducer. Only the collar extends beyond the introducer. Traction on the piston retracts the introducer inside the handpiece. This relative shortening ejects the stent, starting with its free end. The punctal plug is supported by a rigid stylet. The neck of the punctal plug slides inside the longitudinal slit of the introducer and is the last part to leave the introducer. Several lengths of silicone stent are available: 30, 35, 40, 45 and 50 mm.

of other treatment options in combination with LP (stent intubation, turbinate infraction, balloon catheter dilation, etc.) is often close to 95% [1,11,12]. Each treatment has its limitations with or without endoscopic guidance, however [13–17]. Selection bias is also a concern and the various treatment modalities when combined make the conclusions of both published comparative as well as any prospective studies difficult to interpret with any confidence.

The type of anesthesia and laryngeal protection is rarely taken into account when comparing these techniques [18,19]. Use of a simple mask with general anesthesia has considerable risks with most stent intubation techniques other than the pushed intubation types which minimize intranasal manipulations. The Lacrijet (Lcj) is new pushed intubation device for managing CLNDO. It differs from the Masterka (Msk) in that an introducing guide surrounds the silicone stent and can thus provide better protection and minimize bunching of the silicone stent during pushed intubation (Fig. 1). A preliminary study has demonstrated the simplicity of this method of intranasal stent [20].

The initial results of a new Lacrijet design are here reported.

Materials and methods

Study objective

To study the performance of a preloaded Monoka stent (Lacrijet) in the treatment of CNLDO (Fig. 1).

Study design

Non-randomized study of consecutive cases. CNLDO treated by placing a preloaded classical Monoka silicone stent contained entirely inside an introducer guide (Lacrijet).

All of the subject's parents received official written information about the procedure. The ethics committee granted approval (IRB 00008855 *Société Française d'Ophtalmologie*). Inclusion criteria for the study included congenital nasolacrimal duct obstruction in infants with symptoms persisting beyond age 12 months. The exclusion criteria included subjects with only intermittent tearing, canalicular stenosis, Trisomy 21, facial clefts or any previous history of lacrimal or facial surgery.

Procedure

For each subject general anesthesia was achieved using a laryngeal mask airway. The surgical technique has been described elsewhere [20]. All subjects underwent a probing during the induction phase determines. This allowed the surgeons to better determine three necessary parameters:

- the degree of potential nasolacrimal stenosis;
- proper placement of the stent by intranasal metal-to-metal (MTM) contact;
- the distance between the lacrimal punctum and the nasal floor.

The Lacrijet (Lcj) was used in the following manner. The lacrimal catheter was advanced until it was touching the nasal floor. The handpiece was then retracted by one millimeter, to prevent damaging the mucosa, which could lead to unexpected movement (Fig. 2). If the anchoring plug was touching the punctum from the outset, continuous traction was sufficient for ejection of the stent from the introducer. Otherwise, a step-by-step approach was required for proper stent seating. This involved traction that was applied to the piston for approximately 2 to 3 mm. This retracted the introducer inside the handpiece, and ejected the free part of the Lcj, over the same length. The stent was pushed down by

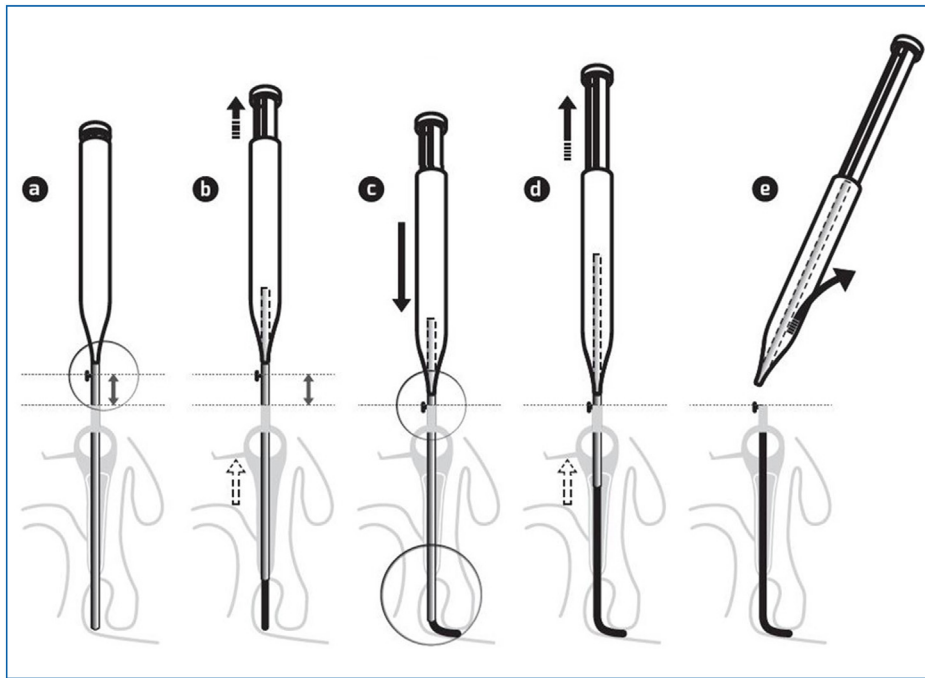


Figure 2. Stent placement: Application of the punctal plug in contact with the lacrimal punctum is an absolutely essential step for all self-retaining stents. (a) Nasolacrimal duct intubation as far as the floor of the nasal cavity. The initial intubation always stops in contact with the nasal cavity. Removal of the safety pin. (b) The first traction on the piston is limited to about 2–3 mm to withdraw the introducer from the floor of the nasal cavity and to eject the stent by about 2–3 mm. (c) The introducer can then be advanced in contact with the floor of the nasal cavity. The flexibility of the silicone stent does not interfere with this second progression. At this stage, if the punctal plug is still not in contact with the lacrimal punctum, the same sequence is repeated. (d) Once the punctal plug has been correctly placed over the lacrimal punctum, the piston can be fully actuated. (e) After the introducer has been completely removed, the punctal fixation plug is inserted into the vertical canaliculus. This approach avoids compressing the stent in the canaliculus, associated with a risk of expulsion, without sacrificing the safety distance beyond the nasolacrimal valve. APP can be immediately in contact when the Punctum-nasal floor length is a multiple of 5; steps b and c are useless.

approximately 2 to 3 mm, until it was touching the nasal floor. The previous steps were repeated until the anchoring plug was touching the lacrimal punctum. Traction was then applied to the piston up to the abutment, in order to eject the remaining portion of the stent. The anchoring punctal plug (APP) was inserted into the vertical canaliculus using the insertion instrument, ensuring that the collar was stable in the punctal meatus and resting on the lid margin. Anesthetic eye drops and an antibiotic ointment were instilled.

Every subject was treated with a post-operative regimen of neomycin and dexamethasone drops in the operative eye three times a day for seven days.

Follow-up visits were scheduled for one day post-operative (for a cornea evaluation) and one month later for stent removal.

As part of the surgery the following was noted:

- the degree and location of nasolacrimal stenosis, Anything other than a simple Hasner membrane stenosis is considered as complex obstruction;
- the metal to metal test confirming proper location through the valve of Hasner;
- any surgical difficulties or complications;
- the duration of surgical intervention: between dilation of lacrimal punctum and insertion of the APP;
- tolerance to the anchoring punctal plug (APP);
- inspection of the Lacrijet silicone after withdrawal.

Results

Thirty-nine pediatric subjects (45 total sides) with persistent symptoms of CNLDO underwent consecutive surgery using a blind pushed lacrimal intubation technique (Lacrijet). All subjects were treated from May 2019 to March 2020 by the same two surgeons (BF, JMR).

Three groups were retrospectively established, depending on the results of simple probing in the OR:

Group A: complex stenosis (4 sides). Attempted pushed intubation was unsuccessful in 2 cases but two pulled intubation procedures were successfully performed during the same operating session. Two other Lacrijet intubations were done but ultimately failed due to complex stenosis. The success rate in group A was 50% (2/4). The average age was 32.3 months and average follow-up was 6.5 months.

Group B: simple mucosal stenosis but questionable MTM contact (3 sides). Endoscopic examination confirmed proper placement and pushed Lacrijet stents were then inserted. The success rate in the group was 100% (3/3) with an average age of 49.5 months and the average follow-up of 8.2 months.

Group C: simple mucosal stenosis done with Lacrijet stent insertion and positive MTM contact (38 sides). The mean age was 25.8 months (range: 12 to 78 months). The average duration of each operative procedures was less than two minutes. The mean duration of intubation before planned extubation was 32 days. Surgery was successful in 92.2% (35/38) of the

Table 1 Postoperative results by groups A, B and C for simple vs. complex stenosis with and without metal to metal intranasal confirmation of probe placement.

Group	A	B	C
n = 43	2 ^a	3	38
Age	32 m	49.5 m	25.8 m
(Range)	(22–40)	(45–57)	(12–78)
Intubation	5.5 D	28 D	32 D
Duration	(2–9)	(1–43)	(1–103)

^a 2 Lacrijets were removed in the OR.

cases. The mean follow-up was 7.9 months (range: 1 to 12 months) (Tables 1 and 2).

There were few intra-operative failures noted in this series and these were essentially related to minor equipment problems. 3 devices failed intra-operatively and were replaced during the procedure without incident. These included separation of the plug collar from the bulb, retention of the punctal plug within the introducer and premature extubation of the stent [20]. These intra-operative encounters are summarized in Table 3. Spontaneous extubations of the plug were easy to insert and when compared with the Masterka no accordion effect was encountered [21]. The only postoperative complication noted was a single corneal abrasion, which healed with medical management. There were no other post-operative complications such as preseptal cellulitis or punctal/canalicular slitting. This is summarized in Table 4. The procedures which took the longest time corresponded to those that involved the replacement of equipment, use of endoscopy (Group B) or conversion into a pulled intubation (Group A) if stenosis in the duct affected the pushed intubation technique.

Discussion

Lacrijet intubation can follow a routine lacrimal probing (LP). The lacrimal punctum needs to be dilated further, however, to comfortably accept the diameter (0.9 mm) of the introducer, which is comparable to the metal probe of traditional pulled intubation systems. Insertion must be gradual and gentle. In this series no punctal ruptures or slitting of the canaliculus were observed. The absence of epistaxis in all cases raises the question of whether laryngeal mask protection is mandatory. Five sides were operated under spontaneous ventilation, using only a face mask, and no

specific difficulties were encountered. This choice was entirely based, however, on the decision of the anesthetist.

The Lacrijet is not appropriate for every case of CNLDO. Determining the correct indications is essential

The anatomical nature of CNLDO is one of the two most important parameters. Determining the correct indications is essential (Fig. 3). Screening is performed “blind”, essentially via tactile sensation during lacrimal probing. The lumen of the lacrimal sac and the nasolacrimal duct are normally straight and almost directly aligned with one another. This allows the probe to easily reach and perforate the mucosal block at the valve of Hasner with minimal risk.

In approximately 10% of cases, however, this “intubation-breach-release” sequence deviated from the ideal plan. Bone abnormalities (blind duct, inflection, curving, compression, impacted inferior turbinate, etc.) may make physiological intubation difficult, regardless of the type of intubation system used. Intra-lacrimal endoscopy has confirmed the possibility of false passages inside the walls of the nasolacrimal duct [13–16]. They cannot be easily detected, however, and are extremely challenging to correct using rhinoscopy. Additionally, while catheterization of the canal may seem easy, an unusually thick mucosa can occasionally be encountered at the distal end, which can prove difficult to perforate [17]. The prognosis is usually poorer in all such complex cases, regardless of the intubation method chosen.

With complex stenosis of the nasolacrimal duct, the Masterka insertion risks the silicone stent folding on itself like an accordion and thus remaining upstream in the canal [21]. The Lacrijet offers more security, however, as the silicone stent is protected by the introducer passing through the valve of Hasner with the stent remaining in position as the introducer is withdrawn. Of the 39 stents examined postoperatively, all were intact, including the four from group A with complex stenosis. Intubation is just one aspect, however. When a prolonged intubation occurs, especially with ductal stenosis, a pulled intubation technique is unrivaled and it is best to recognize this and move to this method of intubation [1,22]. In group A, both conversions to a pulled intubation were successful, while both Lcj procedures utilized with complex stenosis of the duct failed. As a result, the Lcj is no longer recommended for cases of complex stenosis.

A second important aspect to assess is the ease of movement of the introducer down the nasolacrimal duct. At the

Table 2 Postoperative results by groups A, B and C for simple vs. complex stenosis by age categories yearly from age 12 to 48 months.

AgeGroup A ^a +B+C	12–24 months	25–36 months	37–48 months	> 48 months
Total (n = 43)	22	9	10	2
Failures (n = 5)	4.5% (1/22)	11.1% (1/9)	30% (3/10)	0
Success (n = 38)	95.4% (21/20)	88% (8/9)	70% (7/10)	100% (2/2)

^a n = 2.

Table 3 Operative difficulties comparing original vs. current Lacrijet modification.

Operative difficulties	n =	Problematic contact between punctal plug and lacrimal punctum	Premature punctal plug dislocation	Separation of plug collar from bulb	Retention punctal plug in the introducer	Mean operative time	Epistaxis	Anesthesia
Lacrijet 1*	28	14.2% (4/28)	17.8% (5/28)	0	7.1% (2/28)	/	None	Laryngeal mask
This study	45	2.2% (1/45)	4.4% (2/45)	2.2% (1/45)	8.8% (4/45)	2.8 min	None	Laryngeal mask/ facial mask

Table 4 Operative considerations and postoperative complications for groups A, B and C.

		Group a	Group b	Group c	Total
Data	n =	4	3	38	45
	Age mean (Range)	32.2 m (22–40)	49.5 m (43–55)	25.8 m (12–78)	27.9 m (12–78)
Selection	Complex stenosis ^a	4 ^a	None	None	8.8% (4/45)
Catheterism	Metal to metal Operative time (range)	Not applicable 8 min (2–10)	Questionable 10 min (10–10)	Positive 2 min (1–7)	/ 2.8 min (1–10)
Tolerance & complications (N = 43 ^a)	Corneal abrasion Loss	0 0 ^a	1 0	0 10.5% (4/38)	2.3% (1/43) 9.3% (4/43)
	Preamature punctal plug dislocation (D2, D9)	100% (2/2)	0	10.5% (4/38)	13.9% (6/43)
	Migration	0	0	0	0
	Inspection of the removed silicone stent	All 4 intact ^a	All 3 intact	32/32 ^b	

Anything other than simple Hasner membrane stenosis is considered as complex obstruction.

^a Conversion to Pulled Monoka = 2.

^b 2 Stents not reported.

end of catheterization, it should normally emerge between the lateral wall and the inferior turbinate. If the introducer doesn't reach this area, it will not be able to assist in placing the stent correctly. When there is positive MTM contact, the nasal probe can move the lacrimal probe or introducer from one side to the other. This freedom translates that the introducer is in the inferior nasal meatus. With a little experience and a soft touch, neither MTM contact nor the intubation will cause epistaxis.

When the sensation is negative or questionable, a sub-mucosal trajectory should be feared. Endoscopic studies have demonstrated that this occurs in approximately 15% of cases, despite the surgeon deeming that the catheterization was satisfactory [23–29]. MTM sensitivity has been criticized, but it is really one of the two pillars of screening for a successful intubation. While it is subjective and depends on clinical experience, it is of great value in achieving a satisfactory intubation [5,30,31].

Endoscopic correlation has demonstrated that this test gives the correct response in 80% of cases [20,32].

The Lacrijet is the third generation of self-retaining punctal fixation nasolacrimal stent systems. The side effects of this latest system have proven comparable to other two generation of intubation sets [22,33–43]. This is summarized in Table 5.

A single case of corneal abrasion has been reported in this series. This required early removal of the stent but had no lasting functional consequences to the either cornea or to a recurrence of epiphora.

As with other self-retaining punctal fixation probes, the quality of the anchoring plug insertion into the vertical canaliculus determines stability. Likewise, for the duration of intubation, the consequence of instability is premature extrusion.

The factors likely to compromise the stability of self-retaining punctal fixation are well known: punctotomy, stricturotomy, engaging the anchoring plug by applying traction to the stent in the nasal cavity, suturing the stent in the nasal fossa, or duration of intubation longer than two or three months [22]. In addition, for pushed intubation, it is

Table 5 Comparison of published self-retaining punctal fixation nasolacrimal stent systems.

	Silicone stent	Introducer	Autors	Year	Stenosis	n =	Average age (month)	Average duration intubation (month)	Early stent loss (%)	Corneal abrasion	Succes	Average follow-up (months)
Self-retaining punctal fixation nasolacrimal stent systems	Monoka	Pulled intubation	Fayet	1993	Unspecified	43	64 m	5.1 m	18.6	2.3%	91%	10 m
			Kaufman	1998	Unspecified	48	31 m	NP	44	6.2%	79%	4 m
			Fayet & ruban	2005	Unspecified	1028	22 m	2.7 m	19.5	1.2%	90.6%	10 m
			Engel	2007	Simple= 494/ complex = 95	803	15 m	2 m	14.5	2%	96% (96.6/95.3)	3 m
	Masterka (pushed intubation)	Stent within introducer	Dotan	2015	Unspecified	54	37 m	2.5/4.7 m	44	NP	71/83%	NP
			Fayet	2012	Simple	110	28 m	1.3 m	15	NP	85%	8.4 m
			Andalib	2014	Unspecified	25	26 m	NP	30	0	50%	NP
			Goldstein	2014	Unspecified	35	25 m	NP	11	5.7%	91%	NP
			Khatib	2014	Simple/ complex	17/55	22 m	NP	18	np	88/71%	14 m
			Alanon	2015	Unspecified	40	31 m	NP	15	2.5%	97.5%	15 m
			Elsawaby	2016	Simple	30	14 m	1-3 m	3.3	?	83.3%	4 m
	Lacrijet (pushed intubation)	Introducer surrounds stent	Rajabi	2016	Unspecified	38	/	3 m	2.2	0	47.3%	6 m
			This study-groupe c	2020	Simple	38	26 m	1.1 m	21	2.4%	92.2%	7.9 m

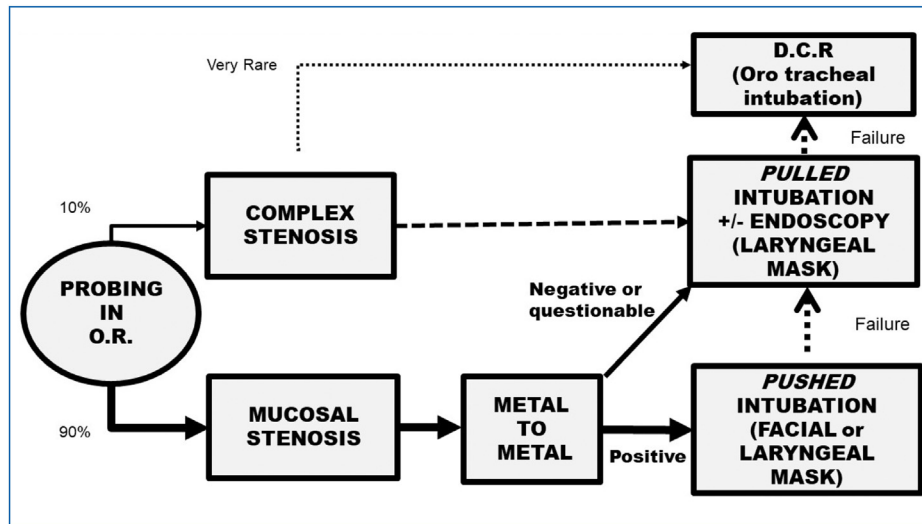


Figure 3. Decision tree based on lacrimal probing in the operating room for managing simple and complex forms of nasolacrimal duct stenosis.

essential that the canaliculus not be compromised [37]. The anchoring plug should just be touching the lacrimal punctum before engaging the bulb in the vertical canaliculus. This should be performed using the insertion instrument. The further the deviation from these recommendations, the higher the rate of premature extrusion is likely to result.

There is no consensus regarding the ideal duration of stent intubation [3,44,45]. If it is too short, there is a risk of failure. Conversely, if it's needlessly long, tolerance may be impaired. Unfortunately, the guideline is empirical by necessity, as there are numerous exceptions. Intubation for a few days, or even a few hours, is sometimes sufficient. Simple LP would probably also suffice in such cases, but how can this be determined beforehand remains a source of controversy. Conversely, prolonging intubation for several months does not guarantee results, even if it is anatomically well tolerated. If the initial catheterization inserted the silicone into a false passage, a foreign body reaction will occur. In such cases, the best of stents would be ineffective. In our experience with intubations, a period of three consecutive weeks without localized or systemic treatment usually is indicative of a successful final result. This corresponds to one month after the procedure.

In this series, none of the cases that became asymptomatic during the month of intubation relapsed after the stent was removed. The failures occurred well before the silicone was removed. This supports our choice of time frame.

We found no significant differences depending on age, sex, uni- or bilaterality, anesthesia, surgeon, probe length, and surgical speed (Table 3). Two items more frequently associated with failure, however: were complex stenosis and an intubation retention of less than a week.

Conclusions

Lacrijet™ results are better than those of our simple probing experience and very similar to those of our intubation results with other methods [21,37]. It is difficult to know whether the credit goes to the rigor of the selection process

or to the new intubation stent system. Classically, beyond the age of one year, the therapeutic choice has usually been made between a simple LP and more complex treatments (pushed intubations, turbinate infraction, or balloon dacryoplasty) with or without rhinoscopy [25,46,47]. Simplicity versus achieving the optimum result is always the question. We believe that the Lacrijet™ intubation system presented here can improve the results of stent intubation for CLNDO without giving up the simplicity of simple nasolacrimal probing alone, and it spares the need for intranasal manipulation.

Disclosure of interest

Bruno Fayet holds the patent for the "Masterka" and the "Lacrijet". Jean-Marc Ruban is paid consultant of FCI. The other authors declare that they have no competing interest.

References

- [1] Katowitz JA, Welsh MG. Timing of initial probing and irrigation in congenital nasolacrimal duct obstruction. *Ophthalmology* 1987;94:698–705.
- [2] Wallace EJ, Cox A, White P, Macewen CJ. Endoscopic-assisted probing for congenital nasolacrimal duct obstruction. *Eye (Lond)* 2006;20:998–1003.
- [3] Kashkouli MB, Beigi B, Parvareh MM, Kassaei A, Tabatabaee Z. Late and very late initial probing for congenital nasolacrimal duct obstruction: what is the cause of failure? *Br J Ophthalmol* 2003;87:1151–3.
- [4] Eshraghi B, Khalilipour E, Ameli K, Bazvand F, Mirmohammad-sadeghi A. Pushed monocanalicular intubation versus probing for the treatment of simple and incomplete complex types of congenital nasolacrimal duct obstruction in children older than 18 months old. *Orbit* 2017;36:218–22.
- [5] Fujimoto M, Ogino K, Matsuyama H, Miyazaki C. Success rates of dacryocystitis-guided probing for recalcitrant congenital nasolacrimal duct obstruction. *Jpn J Ophthalmol* 2016;60:274–9.

- [6] Kushner BJ. Primary surgical treatment of nasolacrimal duct obstruction in children younger than 4 years of age. *J AAPOS* 2008;12:427–8.
- [7] Mimura M, Ueki M, Oku H, Sato B, Ikeda T. Evaluation of granulation tissue formation in lacrimal duct post silicone intubation and its successful management by injection of prednisolone acetate ointment into the lacrimal duct. *Jpn J Ophthalmol* 2016;60:280–5.
- [8] Okumus S, Gurler B, Coskun E, Durucu C, Tatar MG, Yayuspayi R, et al. Efficiency of endoscopic imaging in repetitive probing following unsuccessful probing. *Eur J Ophthalmol* 2012;22:882–9.
- [9] El-Mansoury J, Calhoun JH, Nelson LB, Harley RD. Results of late probing for congenital nasolacrimal duct obstruction. *Ophthalmology* 1986;93:1052–4.
- [10] Abrishami M, Bagheri A, Salour SH, Mirdehghan SA. Late probing for congenital nasolacrimal duct obstruction. *J Ophthalmic Vis Res* 2009;4:102–4.
- [11] Pediatric Eye Disease Investigator G, Repka MX, Melia BM, Beck RW, Atkinson CS, Chandler DL, et al. Primary treatment of nasolacrimal duct obstruction with nasolacrimal duct intubation in children younger than 4 years of age. *J AAPOS* 2008;12:445–50.
- [12] Kominek P, Cervenka S, Pniak T, Zelenik K, Tomaskova H, Matousek P. Monocanalicular versus bicanalicular intubation in the treatment of congenital nasolacrimal duct obstruction. *Graefes Arch Clin Exp Ophthalmol* 2011;249:1729–33.
- [13] Ingels K, Kestelyn P, Meire F, Ingels G, Van Weissenbruch R. The endoscopic approach for congenital nasolacrimal duct obstruction. *Clin Otolaryngol Allied Sci* 1997;22:96–9.
- [14] Sasaki H, Takano T, Murakami A. Direct endoscopic probing for congenital lacrimal duct obstruction. *Clin Exp Ophthalmol* 2013;41:729–34.
- [15] Kato K, Matsunaga K, Takashima Y, Kondo M. Probing of congenital nasolacrimal duct obstruction with dacryoendoscope. *Clin Ophthalmol* 2014;8:977–80.
- [16] Heichel J, Bredehorn-Mayr T, Struck HG. Congenital nasolacrimal duct obstruction from an ophthalmologist's point of view: Causes, diagnosis and staged therapeutic concept. *HNO* 2016;64:367–75.
- [17] Gupta N, Neeraj C, Smriti B, Sima D. A comparison of the success rates of endoscopic-assisted probing in the treatment of membranous congenital nasolacrimal duct obstruction between younger and older children and its correlation with the thickness of the membrane at the Valve of Hasner. *Orbit* 2018;37:257–61.
- [18] Movaghar M, Kodsi S, Merola C, Doyle J. Probing for nasolacrimal duct obstruction with intravenous propofol sedation. *J AAPOS* 2000;4:179–82.
- [19] Lala-Gitteau E, Majzoub S, Pisella PJ. Use of MEOPA during nasolacrimal duct probing in children. *J Fr Ophtalmol* 2007;30:924–7.
- [20] Fayet B, Racy E, Katowitz J, Katowitz W, Ruban JM, Bremond-Gignac D. Insertion of a preloaded Monoka stent for congenital nasolacrimal obstruction: Intraoperative observations. A preliminary study. *J Fr Ophtalmol* 2019;42:248–54.
- [21] Fayet B, Racy E, Ruban JM, Katowitz J. Pushed monocanalicular intubation. Pitfalls, deleterious side effects, and complications. *J Fr Ophtalmol* 2011;34:597–607.
- [22] Fayet B, Bernard JA, Assouline M, Benabderrazik S, Pouliquen Y. Bicanalicular versus monocanalicular silicone intubation for nasolacrimal duct impatency in children: A comparative study. *Orbit* 1993;12:149–56.
- [23] Cibis GW, Jazbi BU. Nasolacrimal duct probing in infants. *Ophthalmology* 1979;86:1488–91.
- [24] Sener EC, Onerci M. Reappraisal of probing of the congenital obstruction of the nasolacrimal system: is nasal endoscopy essential? *Int J Pediatr Otorhinolaryngol* 2001;58:65–8.
- [25] Cakmak SS, Yildirim M. Use of endocanalicular dacryocystorhinostomy with multidiode laser in children. *Int J Pediatr Otorhinolaryngol* 2010;74:1320–2.
- [26] Hakim OM, Mandour W, Elbaz E. Nasal endoscopic visualization and management of the leading causes of probing failure. *J Pediatr Ophthalmol Strabismus* 2010;47:214–9.
- [27] Alanon-Fernandez MA, Alanon-Fernandez FJ, Martinez-Fernandez A, del Mar Gorgora M, Calero B, Lopez-Marin I, et al. Comparative study of primary intention lacrimal probing with and without nasal endoscopy. *Acta Otorrinolaringol Esp* 2014;65:297–301.
- [28] Al-Faky YH, Mousa A, Kalantan H, Al-Otaibi A, Alodan H, Alsuhaibani AH. A prospective, randomised comparison of probing versus bicanalicular silastic intubation for congenital nasolacrimal duct obstruction. *Br J Ophthalmol* 2015;99:246–50.
- [29] Gupta N, Chawla N, Ganesh S, Das S, Dhawan N, Bansal S, et al. Prevalence of buried probe in complex congenital nasolacrimal duct obstruction and evaluation of its success rate post probing and irrigation: a single-centre retrospective study. *Orbit* 2018;37:397–400.
- [30] Yagci A, Karci B, Ergezen F. Probing and bicanalicular silicone tube intubation under nasal endoscopy in congenital nasolacrimal duct obstruction. *Ophthalmic Plast Reconstr Surg* 2000;16:58–61.
- [31] Al-Faky YH. Nasal endoscopy in the management of congenital nasolacrimal duct obstruction. *Saudi J Ophthalmol* 2014;28:6–11.
- [32] Mocan MC, Gulmez Sevim D, Kocabeyoglu S, Irkec M. Prognostic value of metal-metal contact during nasolacrimal duct probing. *Can J Ophthalmol* 2015;50:314–7.
- [33] Kaufman LM, Guay-Bhatia LA. Monocanalicular intubation with Monoka tubes for the treatment of congenital nasolacrimal duct obstruction. *Ophthalmology* 1998;105:336–41.
- [34] Fayet B, Ruban J-M. Intubations lacrymales. Paris: Masson; 2005.
- [35] Engel JM, Hichie-Schmidt C, Khammar A, Ostfeld BM, Vyas A, Ticho BH. Monocanalicular silastic intubation for the initial correction of congenital nasolacrimal duct obstruction. *J AAPOS* 2007;11:183–6.
- [36] Dotan G, Ohana O, Leibovitch I, Stolovitch C. Early loss of monocanalicular silicone tubes in congenital nasolacrimal duct obstruction: incidence, predictors, and effect on outcome. *Int J Pediatr Otorhinolaryngol* 2015;79:301–4.
- [37] Fayet B, Katowitz WR, Racy E, Ruban JM, Katowitz JA. Pushed monocanalicular intubation: an alternative stenting system for the management of congenital nasolacrimal duct obstructions. *J AAPOS* 2012;16:468–72.
- [38] Andalib D, Mansoori H. A comparison between monocanalicular and pushed monocanalicular silicone intubation in the treatment of congenital nasolacrimal duct obstruction. *Int J Ophthalmol* 2014;7:1039–42.
- [39] Goldstein SM, Goldstein JB, Katowitz JA. Comparison of monocanalicular stenting and balloon dacryoplasty in secondary treatment of congenital nasolacrimal duct obstruction after failed primary probing. *Ophthalmic Plast Reconstr Surg* 2004;20:352–7.
- [40] Khatib L, Nazemzadeh M, Revere K, Katowitz WR, Katowitz JA. Use of the Masterka for complex nasolacrimal duct obstruction in children. *J AAPOS* 2017;21:380–3.
- [41] Alanon FJ, Alanon MA, Marin-Gonzalez B, Lopez-Marin I, Olmo N, Martinez A, et al. Self-adjusting monocanalicular intubation for congenital lacrimal obstruction. *Arch Soc Esp Oftalmol* 2015;90:206–11.
- [42] Elsayaby EA, El Essawy RA, Abdelbaky SH, Ismail YM. Pushed monocanalicular intubation versus probing as a

- primary management for congenital nasolacrimal obstruction. *Clin Ophthalmol* 2016;10:1487–93.
- [43] Rajabi MT, Zavarzadeh N, Mahmoudi A, Johari MK, Hosseini SS, Abrishami Y, et al. Bicanalicular versus monocalicular intubation after failed probing in congenital nasolacrimal duct obstruction. *Int J Ophthalmol* 2016;9:1466–70.
- [44] Welsh MG, Katowitz JA. Timing of Silastic tubing removal after intubation for congenital nasolacrimal duct obstruction. *Ophthalmic Plast Reconstr Surg* 1989;5:43–8.
- [45] Eustis HS, Nguyen AH. The treatment of congenital nasolacrimal duct obstruction in children: a retrospective review. *J Pediatr Ophthalmol Strabismus* 2018;55:65–7.
- [46] Gardiner JA, Forte V, Pashby RC, Levin AV. The role of nasal endoscopy in repeat pediatric nasolacrimal duct probings. *J AAPOS* 2001;5:148–52.
- [47] Orhan M, Cal P, Onerci M, Irkec M. Conventional or endoscopic probing for congenital nasolacrimal duct obstruction. *Eur J Ophthalmol* 2001;11:215–7.